



The increased main branch to stent diameter ratio is associated with side branch decreased coronary flow in “true” coronary artery bifurcations treated by “provisional” stenting – a two-dimensional quantitative coronary angiography study

Uvećanje odnosa dijametra glavne grane i veličine stenta povezano je sa smanjenim protokom u bočnoj grani kod “pravih” račvi koronarnih arterija lečenih “provizornom” implantacijom stenta – studija sa dvodimenzionalnom kvantitativnom koronarografijom

Ivan Ilić^{*†}, Radosav Vidaković^{*†}, Aleksandra Janićijević^{*}, Milica Stefanović^{*}, Srdjan Kafedžić^{*}, Milivoje Cerović^{*}, Dušan Milićević^{*}, Gojko Obradović^{*}, Vladimir Jovanović^{*}, Ivan Stanković^{*†}, Biljana Putniković^{*†}, Aleksandar N. Nešković^{*†}

Clinical Hospital Center Zemun, ^{*}Department of Cardiology, Belgrade, Serbia; University of Belgrade, [†]Faculty of Medicine, Belgrade, Serbia

Abstract

Background/Aim. Percutaneous coronary interventions (PCI) in bifurcation lesions having more than 50% stenosis of both the main branch (MB) and the side branch (SB) remain challenging. Measurements of the vessel diameters and angles using quantitative coronary angiography (QCA) software have been used in evaluating PCI outcomes. We investigated potential effects of provisional stenting of the MB on SB coronary blood flow by determining quantitative vessel parameters in “true” non-left main coronary bifurcation lesions using conventional two-dimensional QCA. **Methods.** The study was prospective and conducted in a high-volume university PCI center. Study included patients with “true” native coronary artery bifurcations (Medina 1.0.1; 0.1.1; 1.1.1) treated with “provisional” stenting of the MB. Patients were excluded from the study if having left ventricular ejection fraction of less than 30%, having renal failure with creatinine clearance below 30 mL/kg/m² or bifurcation lesions within the culprit artery causing myocardial infarction, grafted surgically or previously treated by PCI. QCA analysis included measurements of reference vessel diameters (RVD), diameter stenosis (DS) and bifurcation

angles. **Results.** The study included 70 patients with 72 “true” non-left main bifurcations. Most of the bifurcations were located in the left anterior descending (LAD) – diagonal (Dg) territory. Compromise of the SB ostium defined as thrombolysis in myocardial infarction (TIMI) < 3 coronary flow occurred in 17/72 (23.6%) bifurcations. It was treated by either balloon angioplasty only of the SB ostium (9/17, 52.9%) or stent implantation [8/17 (47.1%)]. In a logistic regression analysis, including previously recognized predictors of SB compromise (bifurcation’s angles, RVD, DS and ratio of MB RVD to stent diameter ratio), only MB RVD to stent diameter ratio after PCI remained independent predictor of SB coronary flow compromise after stent implantation in the MB [OR 2.758 (95% CI 1.298–5.862); $p = 0.008$]. **Conclusions.** It appears that SB decreased coronary blood flow after “provisional” stenting in “true” non-left main bifurcations is associated with greater MB to stent diameter ratio.

Key words: percutaneous coronary intervention; stents; blood circulation; coronary angiography.

Apstrakt

Uvod/Cilj. Perkutane koronarne intervencije (PKI) lezija na račvi sa suženjem većim od 50% na glavnoj grani (GG) predstavljaju izazov. Procena dijametara i uglova primenom

programa kvantitativne koronarografije (KK) korišćena je u proceni ishoda PKI. Istraživali smo potencijalne efekte „provizorne“ implantacije stenta u GG na protok u bočnoj grani (BG) određivanjem kvantitativnih parametara krvnog suda kod „pravih“ račvi koje ne zahvataju glavno stablo leve

koronarne arterije, primenom 2D KK programa. **Metode.** Prospektivna studija, sprovedena u univerzitetskom centru sa velikim brojem PKI, uključila je bolesnike sa „pravim“ račvama nativnih koronarnih arterija (Medina 1.0.1, 0.1.1, 1.1.1) lečene „provizornom“ implantacijom stenta u GG. U studiju nisu bili uključeni bolesnici sa ejakcijom frakcijom (EF) manjom od 30%, klirensom kreatinina manjim od 30 mL/kg/m² ili lezijom na račvi odgovornoj za infarkt miokarda, hirurški revaskularizovanoj ili prethodno lečenoj primenom PKI. KK analizom mereni su referentni dijometri (RD) GG i BG, stepen dijametara suženja (DS) i uglovi bifurkacija. **Rezultati.** Studija je uključila 70 bolesnika sa 72 račve. Većina račvi nalazila se u slivu prednje descedentne grane (PDA) – dijagonalna arterija (Dga). Kompromitacija ostijuma BG definisana kao smanjenje koronarnog protoka TIMI < 3 nastala je kod 17/72 (23,6%) račve. Tretirana je

angioplastikom ostijuma BG [9/17 (52,9%)] ili implantacijom stenta [8/17 (47,1%)]. U logističkoj regresionoj analizi koja je uključila prethodno poznate prediktore kompromitacije BG (uglovi bifurkacije, RD, DSi odnos GG RD prema dijametru stenta) samo je odnos RD GG prema dijametru stenta bio nezavisni prediktor smanjenje protoka u GG nakon implantacije stenta [OR 2,758 (95% CI 1,298 – 5,862); *p* = 0,008]. **Zaključak.** Sniženje koronarnog protoka u bočnoj grani nakon „provizorne“ implantacije stenta u glavnu granu, kod „pravih“ račvi koronarnih arterija, povezano je sa uvećanim odnosom dijametara glavne grane prema dijametru stenta na osnovu dvodimenzionalne KK.

Ključne reči:

perkutana koronarna intervencija; stentovi; krv, cirkulacija; angiografija koronarnih arterija.

Introduction

Percutaneous coronary interventions (PCI) on bifurcation lesions comprise about 15–20% of all PCI procedures and are associated with increased incidence of complications and stent thrombosis^{1,2}. “Provisional” stenting is a recommended strategy for most bifurcations, since it provides favorable angiographic and clinical outcomes^{3,4}. Treatment of bifurcation lesions having more than 50% stenosis of both the main branch (MB) and side branch (SB), remains difficult. These, so called, “true” bifurcations are often underrepresented in the clinical trials and their treatment remains challenging. It is conceivable that “provisional” stenting of the MB in “true” bifurcation can further compromise already stenosed SB ostium causing ischemia by “plaque” or “carina shift”^{3,5}. Since visual estimation has been deemed insufficient, two dimensional (2D) quantitative coronary angiography (QCA) is increasingly used in practice and clinical research to assess severity of obstructive coronary artery disease and the efficacy of the PCI^{6,7}. Measurements of the vessel diameters and angles using QCA software before and after the PCI on bifurcations have been used in evaluating outcomes of the interventions and also the mechanism of SB compromise^{4,5}. Since division of coronary arteries at sites of bifurcations follows fractal law and the curvature of the heart causes foreshortening of the vessels, conventional 2D QCA software may not be optimal for the analysis of coronary artery bifurcations^{8,9}. Recently, dedicated packages for bifurcations and three dimensional (3D) QCA software have been developed to further improve bifurcation analysis¹⁰.

We investigated the mechanism of side branch decreased coronary blood flow after “provisional” stenting of the main branch by determining quantitative vessel parameters of both, main and side branch in “true” non-left main coronary bifurcation lesions using conventional two-dimensional quantitative coronary angiography.

Methods

The study was prospective and conducted in a high-volume university PCI center. Study included patients with

“true” native coronary artery bifurcations (Medina 1.0.1; 0.1.1; 1.1.1)¹¹ with > 50% visually estimated stenosis in both MB and SB, with SB diameter greater than 2 mm and SB stenosis extending not more than 5 mm from the ostium. Patients were scheduled to undergo PCI based on clinical findings of stable angina, silent ischemia and/or proven coronary ischemia on functional testing. The patients signed an informed consent form prior to any of the study procedures. The study was approved by the institutional Ethics committee and was done in accordance with Helsinki declaration. This study was the part of project that evaluated “true” coronary bifurcations scheduled for PCI using multimodality imaging with multislice computed tomography coronary angiography, intravascular ultrasound (IVUS) and invasive coronary angiography (study protocol was registered at www.clinicaltrials.gov- NCT01943643).

Patients were excluded from the study if having depressed left ventricular ejection fraction (LVEF) of less than 30% or suffering from renal failure with estimated glomerular filtration rate (GFR) of less than 30 mL/min/m². Patients with GFR between 30 to 60 mL/min were adequately hydrated before PCI. Patients with bifurcation lesions within the culprit artery causing myocardial infarction, grafted surgically or previously treated by PCI, were not considered for the study. Patients having medical condition that can be a contraindication for PCI and/or an allergy to aspirin, clopidogrel, ticagrelor or contrast agent were also excluded from the study.

Initial strategy for PCI was “provisional” stenting of the MB. Vascular access, guiding catheters and coronary wires were chosen by the operators. Heparin in doses of 80–100 IU/kg was used as periprocedural anticoagulation. After placing the guidewires in the MB and SB lesion, the MB was predilated. After adequate predilation, a second generation drug eluting stent (DES) was placed in the MB across the SB, so that its diameter was chosen by the operator based on the visual estimate of the distal MB vessel size and in line with the fractal law of bifurcations⁸. After stenting, proximal optimization technique (POT) of the stent in the MB was performed using high pressure inflation with a short non-compliant balloon catheter, 0.25–0.5 mm larger than the di-

ameter of the stent implanted. After POT and intracoronary nitroglycerin administration, coronary angiograms in two orthogonal projections were done. If coronary blood flow in SB was normal with thrombolysis in myocardial infarction (TIMI) flow grade 3, the procedure was finished. If the flow in the SB was less than TIMI 3, procedure was continued with guidewire exchange, preferably with a third guidewire inserted through the distal strut in the SB. After predilatation of the SB ostium, kissing inflation was done using adequately sized noncompliant balloon catheters in the MB and SB, up to 6–8 atm. After control coronary angiogram, if the SB TIMI flow remained less than 3 or there was an ostial dissection of the SB, another second generation DES was implanted in the SB, using the technique chosen by the operator. The preferred technique was T and protrusion (TAP).

Coronary angiograms before and after PCI were analyzed by experienced interventional cardiologist, not aware of patient clinical and procedural data. Analysis was performed offline using commercially available software package for 2D QCA installed on multimodality workstation Leonardo (Siemens, Erlangen, Germany). The same projections were used for pre- and post-intervention image analyses. End-diastolic frames were selected for interpretation to avoid foreshortening and overlapping of the coronary arteries. The manual calibration was done according to the guiding catheter size. Using automated border detection software, analysis of two vessels was performed, one starting from the proximal MB to distal MB, and another one starting from the proximal MB and towards the SB (Figure 1). The manual corrections were applied in order to include atherosclerotic plaque in MB and at the ostium of the SB that may have been missed by automated detection.

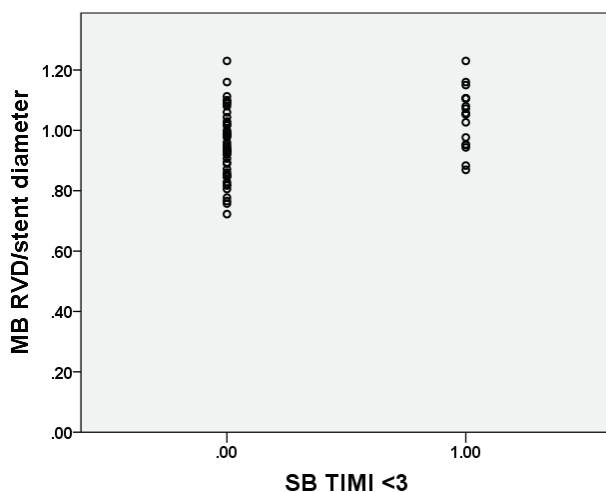


Fig. 1 – Native coronary artery bifurcation LAD–Dg, with the drawing depicting the method of vessel tracing for QCA analysis and acquired measurements. LAD – left anterior descending; Dg – diagonal branch; QCA – quantitative coronary angiography; RVD – reference vessel diameter; TIMI – thrombolysis in myocardial infarction.

The analysis included measurements of the proximal and distal reference diameters in the MB defined as the least

affected segment by atherosclerosis up to 10 mm from the bifurcation plaque. Measurements included SB reference diameters defined as the least diseased segment up to 10 mm distal from the SB ostium, maximum diameter stenosis (DS), area stenosis (AS) of the MB and SB ostium, as well as all bifurcation angles (proximal MB – SB, distal MB – SB, proximal MB – distal MB).

The reproducibility of the QCA parameters measured MB and SB RVD before and after PCI and bifurcation angle B before and after PCI were measured by two experienced observers and twice by each observer in 20 randomly selected patients. Interobserver coefficients of variation for measuring MB and SB RVD before and after PCI and bifurcation angle B before and after PCI were 5%, 7%, 5%, 9%, 5% and 6%, respectively. Intraobserver coefficients of variation for repeated same measurements were 4%, 6%, 5%, 8%, 7% and 3%, respectively.

After the PCI, the patients with uneventful clinical course stayed in the hospital for 24 h. Blood samples for troponin I, creatine kinase (CK) and CK-MB were collected at 12 and 24 h after the procedure, and for C-reactive protein (CRP) after 24h. Complications of the interventions were documented in the patients' study file.

Statistical analysis

Continuous data were summarized as the means \pm standard deviation (sd) or as median value and interquartile range (IQR) depending on distribution. Categorical data were summarized as counts and percentages. Unpaired *t*-test was used for comparing the continuous variables if their distribution was normal and Mann-Whitney *U* test was used for the continuous variables that did not have normal distribution. The chi-squared (χ^2) test and Fisher's exact test were used for categorical variables. The effect of patient's 2D QCA characteristics on endpoint of SB decrease in coronary flow below TIMI 3 were explored using multivariate logistic regression and their impact were expressed as odds ratios (OR) with 95% confidence intervals (CI). A set of variables was selected prospectively, and a stepwise selection process was used to determine independent predictors of SB compromise in a multivariate analysis model. The stepwise selection iteratively selected the most significant variable with multivariate *p*-value < 0.25 , to start the model. At each step, another significant variable was added and after running the model, a check was performed to remove the variable with a multivariate *p*-value > 0.10 . This was repeated with the complete set of variables until no more variables could be entered and no variables could be dropped. The *p* value of $p < 0.05$ was considered to be statistically significant. All statistical analyses were performed using PASW Statistics 18.0 statistical software (SPSS Inc., Chicago, Illinois, USA).

Results

The study included 70 patients with 72 "true" non-left main bifurcations. Patients included in the study had high incidence of hypertension, dyslipidemia and previous myocar-

dial infarction. Also, they had preserved left ventricular ejection fraction and renal function. The clinical characteristics were similar in the groups of patients with or without disturbance of SB coronary flow (Table 1).

Majority of the patients included in the study had two-vessel disease [1 vessel – 17/70 (24.3%), 2 vessel – 43/70 (61.4%) and 3 vessel disease 10/70 (14.3%)]. Most of the bifurcations were located in the left anterior descending (LAD) – diagonal (D) territory in both study groups. Data regarding the distribution of bifurcations and stenosis according to Medina classification were presented in Table 2.

All patients underwent PCI using radial access and 6F guiding catheter. After successful stent implantation and POT, SB decreased coronary flow TIMI < 3 occurred in

17/72 (23.6%) bifurcations. It was treated by either balloon angioplasty only of the SB ostium (9/17, 52.9%) followed by POT (POT – side – POT) or stent implantation (8/17, 47.1%) followed by kissing-balloon inflation and POT (Table 2). All interventions were deemed successful with no significant residual stenosis and final TIMI 3 flow in the MB.

Two-dimensional QCA revealed that only MB reference vessel diameter and residual diameter stenosis were significantly different in the group of bifurcations with SB TIMI < 3 after “provisional” stenting. There was an increase in MB RVD in the group of patients where SB compromise occurred. Also, derived parameter – MB RVD after PCI to implanted MB stent diameter ratio – was significantly greater in the SB compromise group (Table 3, Figure 2).

Table 1

Clinical characteristics of the patients in the study groups

Variable	SB TIMI = 3 (n = 55)	SB TIMI < 3 (n = 17)	<i>p</i>
Age (years), mean ± sd	58 ± 8	61 ± 9	0.242
Male gender, %	72.5	72.2	1.000
Heredity, %	38.1	47.1	0.409
Smoking, %	43.6	29.4	0.177
Hypertension, %	87.2	88.2	0.600
Dyslipidemia, %	63.6	83.3	0.358
Diabetes mellitus (DM), %	16.4	23.5	0.730
Insulin dependent DM, %	7.2	5.9	0.567
PAD, %	3.9	1.1	0.277
Previous MI, %	58.8	44.4	0.409
Previous CVA, %	3.9	0.0	1.000
Previous PCI, %	54.9	55.5	1.000
Previous CABG, %	0.0	0.0	
BMI (kg/m ²), median (IQR)	27.4 (25.7–29.9)	27.9 (26.4–34.3)	0.214
LVEF (%), median (IQR)	50 (40–60)	57 (48–60)	0.184
eGFR (mL/min/m ²), median (IQR)	82 (67–94)	96 (73–112)	0.050

SB – side branch; PAD – peripheral arterial disease; MI – myocardial infarction; CVA – cerebrovascular accident; PCI – percutaneous coronary intervention; CABG – coronary artery bypass grafting; BMI – body mass index; LVEF – left ventricular ejection fraction; eGFR – estimated glomerular filtration rate; sd – standard deviation; IQR – interquartile range.

Table 2

Angiographic and percutaneous coronary intervention characteristics of bifurcations

Bifurcation characteristics	SB TIMI = 3 (n = 55)	SB TIMI < 3 (n = 17)	<i>p</i>
Location, n (%)			
LAD–Dg	38 (69.1)	12 (70.6)	0.576
Cx–OM	13 (23.6)	4 (23.5)	0.594
RCA PD–PL	4 (7.2)	1 (5.9)	0.723
Medina classification, n (%)			0.444
1.0.1	14 (25.5)	2 (11.7)	
0.1.1	18 (32.7)	6 (35.3)	
1.1.1	23 (41.8)	9 (52.9)	
Stent diameter in MB (mm), mean ± sd	3.1 ± 0.4	3.0 ± 0.2	0.243
Stent length in MB (mm), mean ± sd	25.5 ± 6.4	26.4 ± 4.3	0.616
Maximum stent inflation (atm), mean ± sd	14.0 ± 1.43	13.8 ± 1.5	0.484
POT balloon diameter (mm), mean ± sd	3.6 ± 0.4	3.5 ± 0.4	0.504
POT balloon length (mm), mean ± sd	8.2 ± 2.6	8.6 ± 2.2	0.590
POT balloon maximum inflation (atm), mean ± sd	17.7 ± 1.9	17.2 ± 1.8	0.345

Cx – circumflex; Dg – diagonal; LAD – left anterior descending; MB – main branch; OM – obtuse marginal; PD – posterior descending; PL – posterolateral; POT – proximal optimization treatment; RCA – right coronary artery; TIMI – thrombolysis in myocardial infarction; sd – standard deviation.

Table 3
Quantitative coronary angiography characteristics in bifurcations with or without side branch decreased flow

QCA characteristics	SB TIMI = 3	SB TIMI < 3	p-value
	mean ± sd	mean ± sd	
MB RVD before PCI (mm)	2.8 ± 0.2	2.9 ± 0.4	0.373
MB DS before PCI (%)	64 ± 8	66 ± 9	0.425
SB RVD before PCI (mm)	2.4 ± 0.2	2.5 ± 0.3	0.106
SB DS before PCI (%)	59 ± 8	63 ± 8	0.082
MB RVD post PCI (mm)	2.9 ± 0.3	3.2 ± 0.4	0.008
Delta MB RVD (mm)	0.10 ± 0.26	0.27 ± 0.31	0.030
MBDS post PCI (%)	13 ± 9	21 ± 12	0.009
SB RVD post PCI (mm)	2.6 ± 0.3	2.7 ± 0.3	0.507
SB DS post PCI (%)	62 ± 16	64 ± 26	0.656
Angle B before PCI	58 ± 17	59 ± 20	0.886
Angle B after PCI	56 ± 18	58 ± 18	0.825
MB RVD post PCI to SD ratio	0.95 ± 0.11	1.05 ± 0.09	0.001

Angle B – angle between distal MB and SB; **Delta** – change in main branch reference vessel diameter; **DS** – diameter stenosis; **MB** – main branch; **PCI** – percutaneous coronary intervention; **RVD** – reference vessel diameter; **SB** – side branch; **SD** – stent diameter; **TIMI** – thrombolysis in myocardial infarction; **sd** – standard deviation.

Table 4
Univariate and multivariate predictors of side branch compromise (TIMI < 3)

Predictors	Univariate		Multivariate	
	OR (95% CI)	p-value	OR (95% CI)	p-value
Bifurcation angle B	1.005 (0.975–1.036)	0.734	–	–
RVD MB before PCI	2.525 (0.331–19.288)	0.372	–	–
RVD SB before PCI	5.918 (0.654–53.539)	0.114	–	–
MB DS before PCI	1.028 (0.961–1.099)	0.420	–	–
SB DS before PCI	1.067 (0.991–1.150)	0.086	1.074 (0.987–1.169)	0.097
MB DS after PCI	1.078 (1.015–1.145)	0.015	1.038 (0.958–1.126)	0.359
SB DS after PCI	1.007 (0.977–1.038)	0.651	–	–
MB RVD after PCI/SD	2.695 (1.424–5.099)	0.002	2.758 (1.298–5.862)	0.008
Delta MB RVD	8.352 (1.156–60.332)	0.035	2.268 (0.187–27.570)	0.521

Angle B – angle between distal MB and SB; **Delta** – change in main branch reference vessel diameter; **DS** – diameter stenosis; **MB** – main branch; **PCI** – percutaneous coronary intervention; **RVD** – reference vessel diameter; **SB** – side branch; **SD** – stent diameter; **TIMI** – thrombolysis in myocardial infarction; **OR** – odds ratio; **CI** – confidence interval.

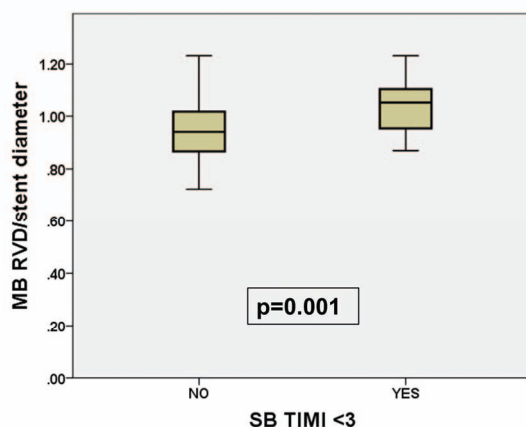


Fig. 2 – Diagram presents the relationship between occurrence of SB compromise defined as TIMI flow < 3 on the X-axis, and a derived variable representing the median value and interquartile range of ratio between the MB reference vessel diameter and stent diameter after stent implantation on the Y-axis.

MB – main branch; **SB** – side branch; **RVD** – reference vessel diameter; **TIMI** – thrombolysis in myocardial infarction.

In a multivariate logistic regression analysis, that included previously recognized predictors of SB compromise (bifurcation angle between distal MB and SB, RVD of MB and SB before and after PCI, DS of MB and SB before and after PCI, change in MB RVD after PCI and ratio of MB RVD/stent diameter), only MB RVD to stent diameter ratio measured after PCI remained independent predictor of SB decreased coronary blood flow after stent implantation in the MB (Table 4).

Discussion

Our study demonstrated that in “true” non-left main native coronary artery bifurcation treated by “provisional” stenting strategy, increase in the MB diameter relative to the diameter of the implanted stent, was independently associated with SB decreased coronary blood flow. To our knowledge, this was not been previously described and it may serve as a measurement of MB vessel enlargement relative to implanted stent diameter. It perhaps may be considered as a surrogate value to evaluate the occurrence of “carina” shift

as a potential mechanism of the SB compromise. Also, despite its inherent limitations, we showed that conventional 2D QCA still can be useful in determining vessel diameters and angles in complex bifurcations and for guiding PCIs.

Atherosclerotic plaques have specific pattern of development in coronary artery bifurcations. They tend to develop in the areas of low endothelial shear stress (ESS), at the lateral walls of bifurcations. Contrary, areas with high ESS, like bifurcation's carina, tend to be spared in the initial development of bifurcation lesion^{12, 13}. We analyzed bifurcations with already advanced atherosclerosis, with large plaque volumes, manifested as significant luminal narrowing of both the MB and SB (Table 3). The SB TIMI < 3 occurred in almost one fifth of the patients. This is probably the consequence of advanced atherosclerotic disease in both the MB and ostium of SB, leading to SB decreased coronary flow after stenting¹⁴.

In our study we used commercially available 2D QCA software. This software ignores the fact that coronary artery bifurcations divide according to the fractal law and that coronary arteries follow three-dimensional curvature of the heart. These could lead to erroneous interpretation of the vessel size and the severity of the atherosclerotic lesions, especially at the points of SB origin¹⁰. Of note, dedicated bifurcation software has been developed, that appreciated the true geometry of the bifurcation and yielded more precise and reproducible bifurcation analysis¹⁵.

The patients in the SB compromise group had greater DS of the SB ostium before the intervention that was no longer true after "provisional" stenting of the MB. Dou et al.¹⁶ incorporated SB ostial stenosis into scoring system to predict SB occlusion after stenting. The higher grade of SB ostial stenosis produced higher score and subsequently higher risk of SB compromise. Similarly, a study using OCT analysis of the bifurcation by Kini et al.¹⁷, demonstrated that SB stenosis is an independent predictor of SB occlusion. In our patients, preprocedural SB DS was not independently associated with decreased coronary flow in the SB. The SB DS before PCI was associated with SB compromise in univariate analysis but this relationship was not confirmed in multivariate model. This may be explained by the fact that we used the 2D QCA software that tends to overestimate significance of SB ostial stenosis and also by the fact that the mechanism of "carina shift" may be predominantly responsible for SB coronary flow compromise^{5, 9, 10, 18}.

Surprisingly, in the multivariate analysis, the angle between distal MB and SB was not associated with SB decreased coronary blood flow. This finding corroborates with some studies that found that either wide or narrow bifurcation angles were not associated with SB compromise^{19, 20}. It is important to notice that our analysis of bifurcation angles was done in two dimensions and did not include assessment of an "inflow" angle of the bifurcation – the angle between the proximal MB and "bifurcation plane", where distal MB and SB are situated. This may have resulted in lack of evidence of association between bifurcation angles, as we calculated them, and the SB flow below TIMI 3²¹. The influence of the bifurcation angle on the fate of the SB after stenting

should probably be studied by appreciating the three dimensional angulation of the coronary arteries and the curvature of the heart.

We showed that only ratio of the MB RVD to stent diameter after PCI was independently associated with decreased SB flow. This relationship perhaps may be the consequence of predominant "carina shift" effect. This phenomenon is the outcome of the stent implantation in the MB that causes movement of the carinal structure of the bifurcation towards the SB leading to its obstruction. Although "plaque shift" can still be the factor in SB compromise, the current paradigm regarding SB compromise after MB stenting is that in most of the cases the SB ostium is jeopardized by "carina shift". This may be further augmented by already present significant ostial disease of the SB, resulting in critical stenosis of the SB ostium after MB stenting^{18, 22}.

The studies using IVUS contributed significantly to the body of knowledge regarding SB compromise and "carina shift". The study by Xu et al.⁵, examined by IVUS both the MB and SB before and after PCI and found that after intervention diameters and volumes of the MB increase, while the opposite occurs at the ostium of the SB. Also, it was demonstrated that SB compromise is frequently caused by vessel volume decrease which is a surrogate of "carina shift", instead of vessel plaque increase, which is a surrogate of "plaque shift". In the study by Koo et al.¹⁸ was also shown that there is a strong correlation between SB ostial compromise and increase in diameters and volumes of distal MB, suggesting that excessive stent expansion can contribute to "carina shift" and increase in ostial SB stenosis. The variable in our study that was independently associated with SB decreased TIMI flow (RVD of the MB to stent diameter ratio), contains the value of stent diameter as an important determinant of vessel enlargement after PCI and possible "carina" shift. Morphology of the carina, evaluated by IVUS, can influence SB compromise in bifurcations without SB ostial disease, as demonstrated by Suárez de Lezo et al.²³, emphasizing the importance of "carina shift" as mechanism causing SB compromise. SB compromise can be further aggravated by stent expansion that exceeds diameter of the main vessel. Our data confirmed that greater expansion of the vessel relative to the stent diameter after "provisional" stenting is independently associated with SB ostial compromise.

Study limitation

In the study we used commercially available 2D QCA software that ignores the laws of bifurcations' division and three-dimensional curvature of the heart. All this can lead to inaccurate measurements of the vessel's dimensions and angles. Also, the variable that was identified as an independent predictor of the SB decreased coronary flow contains the MB dimensions that are measured after the intervention.

Clinical implications

Adequate estimate of the vessel size can be very challenging especially in complex bifurcations and lead to com-

plications of the interventions. Since careful selection of the stent size according to vessel diameter is crucial in provisional stenting of the MB, the results of our study favour the routine use of any available QCA software in planning the procedure.

Conclusion

SB decreased coronary blood flow after “provisional” stenting in “true” non-left main bifurcations is associated with greater main vessel to stent diameter ratio. Two-dimensional QCA, with its known limitations, can still be useful tool in planning complex bifurcation PCI procedures.

R E F E R E N C E S

1. Colombo A, Moses JW, Morice MC, Ludvig J, Holmes DR Jr, Spanos V, et al. Randomized study to evaluate sirolimus-eluting stents implanted at coronary bifurcation lesions. *Circulation* 2004; 109(10): 1244–9.
2. Routledge HC, Lefèvre T, Colombo A, Oldroyd KG, Hamm CW, Guagliumi G, et al. Three-year clinical outcome of percutaneous treatment of bifurcation lesions in multivessel coronary artery disease with the sirolimus-eluting stent: insights from the Arterial Revascularization Therapies Study, part II (ARTS II). *EuroIntervention* 2009; 5(2): 190–6.
3. Lassen JF, Holm NR, Banning A, Burzotta F, Lefèvre T, Chieffo A, et al. Percutaneous coronary intervention for coronary bifurcation disease: 11th consensus document from the European Bifurcation Club. *EuroIntervention* 2016; 12(1): 38–46.
4. Hildick-Smith D, Behan MW, Lassen JF, Chieffo A, Lefèvre T, Stankovic G, et al. The EBC TWO Study (European Bifurcation Coronary TWO): A Randomized Comparison of Provisional T-Stenting Versus a Systematic 2 Stent Culotte Strategy in Large Caliber True Bifurcations. *Circ Cardiovasc Interv* 2016; 9(9): pii: e003643.
5. Xu J, Hahn JY, Song YB, Choi SH, Choi JH, Lu C, et al. Carina shift versus plaque shift for aggravation of sidebranch ostial stenosis in bifurcation lesions: volumetric intravascular ultrasound analysis of both branches. *Circ Cardiovasc Interv* 2012; 5(5): 657–62.
6. Reiber JH. Introduction to QCA, IVUS and OCT in interventional cardiology. *Int J Cardiovasc Imaging* 2011; 27(2): 153–4.
7. Reiber JH, Serruys PW, Kooijman CJ, Wijns W, Slager CJ, Gerbrands JJ, et al. Assessment of short-, medium-, and long-term variations in arterial dimensions from computer-assisted quantitation of coronary cineangiograms. *Circulation* 1985; 71(2): 280–8.
8. Huo Y, Finet G, Lefèvre T, Louvard Y, Moussa I, Kassab GS. Which diameter and angle rule provides optimal flow patterns in a coronary bifurcation? *J Biomech* 2012; 45(7): 1273–9.
9. Lansky A, Tuinenburg J, Costa M, Maeng M, Koning G, Popma J, et al. European Bifurcation Angiographic Sub-Committee. Quantitative angiographic methods for bifurcation lesions: a consensus statement from the European Bifurcation Group. *Catheter Cardiovasc Interv* 2009; 73(2): 258–66.
10. Ishibashi Y, Grundeken MJ, Nakatani S, Iqbal J, Morel MA, Genereux P, et al. In vitro validation and comparison of different software packages or algorithms for coronary bifurcation analysis using calibrated phantoms: implications for clinical practice and research of bifurcation stenting. *Catheter Cardiovasc Interv* 2015; 85(4): 554–63.
11. Medina A, Suárez de Lezo J, Pan M. A new classification of coronary bifurcation lesions. *Rev Esp Cardiol* 2006; 59(2): 183. (Spanish)
12. Stone PH, Saito S, Takahashi S, Makita Y, Nakamura S, Kawasaki T, et al. PREDICTION Investigators. Prediction of progression of coronary artery disease and clinical outcomes using vascular profiling of endothelial shear stress and arterial plaque characteristics: the PREDICTION Study. *Circulation* 2012; 126(2): 172–81.
13. Grotttum P, Svindland A, Walloe L. Localization of atherosclerotic lesions in the bifurcation of the main left coronary artery. *Atherosclerosis* 1983; 47: 55–62.
14. Sakamoto N, Hoshino Y, Mizukami H, Sugimoto K, Yamaki T, Kunii H, et al. Intravascular ultrasound predictors of acute side branch occlusion in coronary artery bifurcation lesions just after single stent crossover. *Catheter Cardiovasc Interv* 2016; 87(2): 243–50.
15. Grundeken MJ, Ishibashi Y, Ramcharitar S, Tuinenburg JC, Reiber JH, Tu S, et al. The need for dedicated bifurcation quantitative coronary angiography (QCA) software algorithms to evaluate bifurcation lesions. *EuroIntervention* 2015; 11 (Suppl V): V44–9.
16. Dou K, Zhang D, Xu B, Yang Y, Yin D, Qiao S, et al. An angiographic tool for risk prediction of side branch occlusion in coronary bifurcation intervention: the RESOLVE score system (Risk prEdiction of Side branch Occlusion in coronary bifurcation interVENTion). *JACC Cardiovasc Interv* 2015; 8(1 Pt A): 39–46.
17. Kini AS, Yoshimura T, Vengrenyuk Y, Amirian J, Hasan C, Baber U, et al. Plaque Morphology Predictors of Side Branch Occlusion After Main Vessel Stenting in Coronary Bifurcation Lesions: Optical Coherence Tomography Imaging Study. *JACC Cardiovasc Interv* 2016; 9(8): 862–5.
18. Koo BK, Waseda K, Kang HJ, Kim HS, Nam CW, Hur SH, et al. Anatomic and functional evaluation of bifurcation lesions undergoing percutaneous coronary intervention. *Circ Cardiovasc Interv* 2010; 3(2): 113–9.
19. Hahn JY, Chun WJ, Kim JH, Song YB, Oh JH, Koo BK, et al. Predictors and outcomes of side branch occlusion after main vessel stenting in coronary bifurcation lesions: results from the COBIS II Registry (CORONARY Bifurcation Stenting). *J Am Coll Cardiol* 2013; 62: 1654–9.
20. Kang SJ, Mintz GS, Kim WJ, Lee JY, Oh JH, Park DW, et al. Changes in left main bifurcation geometry after a single-stent crossover technique: an intravascular ultrasound study using direct imaging of both the left anterior descending and the left circumflex coronary arteries before and after intervention. *Circ Cardiovasc Interv* 2011; 4(4): 355–61.
21. Medrano-Gracia P, Ormiston J, Webster M, Beier S, Young A, Ellis C, et al. A computational atlas of normal coronary artery anatomy. *EuroIntervention* 2016; 12(7): 845–54.
22. Gwon HC, Song YB, Pan M. The story of plaque shift and carina shift. *EuroIntervention* 2015; 11 Suppl V: V75–7.
23. Suárez de Lezo J, Medina A, Martín P, Novoa J, Suárez de Lezo J, et al. Predictors of ostial side branch damage during provisional stenting of coronary bifurcation lesions not involving the side branch origin: an ultrasonographic study. *EuroIntervention* 2012; 7(10): 1147–54.

Received on December 28, 2017.

Revised on February 21, 2018.

Accepted on February 28, 2018.

Online First March, 2018.